

W Laser eye surgery for refractive errors

Tohru Sakimoto, Mark I Rosenblatt, Dimitri T Azar

Lancet 2006; 367: 1432–47

Published Online

March 7, 2006

DOI:10.1016/S0140-

6736(06)68275-5

Massachusetts Eye and Ear
Infirmary, the Schepens Eye
Research Institute, Harvard
Medical School, Boston, MA,

USA (T Sakimoto MD,

M I Rosenblatt MD,

Prof D T Azar MD)

Correspondence to:

Prof Dimitri T Azar, Cornea and
Refractive Surgery Services,
Massachusetts Eye and Ear
Infirmary, 243 Charles Street,
Boston, MA 02114, USA
dazar@meei.harvard.edu

Several laser and non-laser refractive surgical procedures have been used to modify the shape of the cornea and correct myopia, hyperopia, astigmatism, and presbyopia. Introduction of the excimer laser to reshape the cornea has resulted in remarkable developments in the correction of these refractive errors. Combined with other advanced ophthalmological instruments, laser refractive eye surgery has resulted in a substantial rise in the safety, efficacy, and predictability of surgical outcomes. Despite these advances, certain limitations and complications persist. In this review, we describe the history, preoperative assessment, surgical techniques, outcomes, and complications of laser refractive surgery.

The function of the anterior segment of the eye (cornea and lens) is to focus incoming rays of light onto the light-sensing element of the eye—the retina. The bending of incoming light rays, termed refraction, is predominantly done by the cornea at the interface between air and the tear film. Of the 60 D of total refraction, about two-thirds is achieved by the cornea.¹ The remainder of the refractive power is provided by the lens, which is also capable of changing its shape to modulate the total refractive power.

Refractive errors have been traditionally divided into categories on the basis of the location of the focus of parallel light rays, emanating from infinity (equivalent to a distant object), relative to the retina. Emmetropia describes a refractive situation in which the light rays are perfectly focused on the fovea. Myopia (near-sightedness) arises when the light rays are focused in front of the retina. The hyperopic (far-sighted) eye focuses rays from distant objects at a theoretical point behind the retina. Astigmatism represents the differential focusing of light passing through various corneal meridians. The emmetropic, myopic, or hyperopic eye focuses light in a way similar to a spherical lens, and the astigmatic eye focuses light like a spherocylindrical lens (see panel for definitions of terms used in this review).

A complex optical system, such as the human eye, cannot merely be divided into spherical and cylindrical components, although the prescription of glasses does just that. Wavefront aberrometry has become available for the measurement of more subtle, and often major, optical aberrations in the eye.² These aberrometers measure how the optical system alters a wavefront of light entering the eye or emanating from the retina. Alterations can then be analysed to separate the aberrated wavefront into components, using either Zernike polynomials or Fourier analysis.³ Detailed descriptions of these techniques are beyond the scope of this review, but how these wavefront aberrations can be treated with laser refractive surgery, one of the most important advances in refractive surgery, is described below.

History of refractive surgery

Although scientists such as Da Vinci proposed theories as to the source of refractive errors,⁴ the first systematic analysis of the nature and results of refractive errors came from Francis Cornelius Donders. His classic treatise, “On the anomalies of accommodation and refraction of the eye”, outlined the fundamental principles of physiological optics.⁵ Ironically, in this treatise, Donders railed against

Search strategy and selection criteria

We reviewed excimer laser refractive surgical procedures, and excluded other refractive surgical procedures, which do not need laser treatment, such as radial keratotomy, astigmatic keratotomy, epikeratoplasty, thermokeratoplasty, intrastromal corneal implants, and phakic intra-ocular lenses. Our search for outcomes data focused primarily on a search of the US Food and Drug Administration (FDA)-approved clinical trials database for laser vision correction (for US FDA approved clinical trials database see <http://www.fda.gov/cdrh/LASIK/lasers.htm>), which provided the largest and best controlled cohort of laser refractive surgery patient data. Furthermore, we undertook a comprehensive review of PubMed databases for relevant topics with emphasis on review articles, randomised clinical trials, original articles, including prospective and retrospective studies, and case reports with the key words “refractive surgery,” “laser in situ keratomileusis,” “laser subepithelial keratomileusis,” “Epi-LASIK”, “photorefractive keratectomy,” and “wavefront guided refractive surgery”. Current issues of *Investigative Ophthalmology and Visual Science*, *Ophthalmology*, *Archives of Ophthalmology*, *American Journal of Ophthalmology*, *Cornea*, *Journal of Cataract and Refractive Surgery*, and *Journal of Refractive Surgery* were thoroughly examined for articles that might have been missed by the PubMed search. We searched publications from the past 10 years, and reviewed the papers identified and their references. Relevant information from recent ophthalmic corneal and refractive surgical textbooks was also identified. For every study included in this review, the quality of the study was assessed. Masked, prospective, randomised trials were deemed to represent the best quality evidence, followed by cohort studies, then retrospective studies, and finally case series and case reports. Although the FDA data used in this article represented uncontrolled cohort studies, the surveillance provided by FDA monitoring and review resulted in a better quality than that of non-FDA studies with the same basic design. Furthermore, the number of patients included in the FDA-sponsored trials was large, which added to the importance of these studies in assessing the refractive surgical outcomes.

surgical attempts to correct refractive errors by altering corneal shape. A procedure associated with corneal incisions to correct astigmatism was later then attempted by Hjalmar Schiøtz in 1885.⁶ Most other early

Panel: Glossary

Accommodation

The adjustment of the total refractive power of the eye to allow seeing at various distances. Accommodation is effected mainly by changes in the convexity of the lens.

Artificial tears

Topical eyedrops, often formulated to match the pH of human tears. Artificial tears are used to soothe the eyes, moisturise dry spots on the eyes, supplement the eye's own tears, and protect the eye from irritation.

Astigmatism

A defect of an ocular structure (most often the cornea), causing parallel rays of light to be refracted without meeting at a single focal point. An imperfect blurred or smeared image is formed on the retina.

Cyclopentolate

An anticholinergic topical eyedrop used, especially in the form of its hydrochloride $C_{17}H_{25}NO_3 \cdot HCl$, to dilate the pupil, and relax the ciliary body of the eye for ophthalmological examination and measurement of the refractive error of the eye in the absence of accommodation.

Emmetropia

The absence of refractive errors of the eye with its accommodation relaxed. In emmetropia, parallel rays of light are all brought accurately to a focus upon the retina of the unaccommodating eye.

Epi-LASIK

Epi-LASIK includes mechanical separation of the corneal epithelial layer, as a sheet, from the underlying stroma. After excimer laser ablation, the epithelial sheet is repositioned over the treatment zone.

Excimer laser

Excimer lasers are ultraviolet gas lasers. The term excimer is a contraction of excited dimer. At first, intermediary structure for the excited state of these laser heads was thought to include the formation of dimers, two atoms of the same element. Although the gas halide is now recognised as the activated intermediary, instead of a dimer, the term excimer is broadly accepted.

Femtosecond laser

Femtosecond lasers are neodymium glass lasers able to generate femtosecond pulses with high output and short exposure time. The pulses are focused to preset depths below the corneal surface. Blunt separation of the photodisrupted corneal stroma creates the LASIK flap.

Flying spot

Flying spot ablation uses a computer-controlled small fixed diameter beam that allows for peripheral ablation or customised ablation pattern. This technique needs prolonged ablation time, and, not uncommonly, it is coupled with eye-tracking systems.

Hyperopia

A condition in which visual images come to a focus behind the retina of the eye. Accommodation often improves distance vision, but might not be sufficient to improve near vision.

Keratotomy

Surgical excision of part of the cornea.

Keratoconus

Progressive thinning of the central cornea, resulting in corneal bulging and formation of a rounded cone. Keratoconus produces moderate to severe corneal distortions and is often associated with myopia and irregular astigmatism.

Keratomileusis

Keratoplasty in which the anterior lamellae of the cornea are removed, frozen, reshaped, and reinserted to correct refractive error.

Laser in-situ keratomileusis

LASIK is a refractive surgical procedure that permanently changes the shape of the cornea with an excimer laser and a microkeratome or femtosecond laser. The microkeratome or femtosecond laser produces a hinged lamellar flap in the cornea. The flap is folded back, exposing the corneal stroma. Pulses from a computer-controlled excimer laser vapourise a portion of the stroma before the flap is replaced.

Myopia

A condition in which parallel rays of light are bent to a focus in front of the retina of the eye. In myopia, the cornea might be too steep or the axial length of the eyeball might be too long, resulting in defective vision of distant objects.

Presbyopia

A visual condition that generally becomes apparent in middle age and in which loss of elasticity of the lens of the eye causes defective accommodation and inability to focus sharply for near vision.

Photorefractive keratectomy

The use of laser ablation to reshape the stromal surface of the cornea for the correction of myopic or hyperopic refractive errors, or both.

Phototherapeutic keratectomy

A method to treat corneal pathology using ablative laser energy.

Radial keratotomy

A surgical operation on the cornea to correct myopia. This operation includes making a series of incisions in a radial pattern, resembling the spokes of a wheel, to flatten the cornea.

Visual acuity

The relative ability of the visual system to resolve detail, usually expressed as the reciprocal of the minimum angular separation, in minutes of arc, of two lines just resolvable as separate and that forms in the average human eye an angle of one minute of arc; often measured by Snellen test, a test presenting letters of graduated sizes to establish the smallest size that can be read at a standard distance (a 20/20 letter located 20 ft away from an eye subtends an angle of 5 minutes of arc at the eye). The normal acuity in the human eye is 20/20, although some eyes are capable of 20/15 or even 20/10 acuity.

attempts at refractive surgery were also limited to the use of incisions to treat astigmatism.⁷⁻⁹

Modern refractive surgery extended corneal reshaping to treat myopia and astigmatism. Throughout the 1930s and 1940s, Sato¹⁰ published several reports, describing his attempts to refine incisional refractive surgery with anterior and posterior corneal incisions. The Russian ophthalmologist, Fyodorov¹¹ later developed a systematic process of anterior radial keratotomy and treated thousands of myopic patients with greater predictability.

Lamellar surgery was first introduced by Jose Barraquer;¹² he invented keratoplasty procedures that involved the transplantation of corneal tissue of a size different from the host size to alter the curvature of cornea. He also invented a series of lamellar procedures and developed a formula that represented the relation between the added corneal thickness and the change in refractive power, later called Barraquer's law of thickness.¹³

The transition from incisional to ablative laser refractive surgery arose with the development of excimer laser technology. Although lasers were initially used to create anterior radial keratotomy incisions or for thermal shrinkage of collagen-laden corneal tissue (in the form of laser thermal keratoplasty), the most successful and widely used technique is ablation of corneal tissue with the excimer laser. Excimer lasers use argon fluoride gases to emit ultraviolet laser pulses. Taboda and Archibald¹⁴ reported the use of the excimer laser to reshape the corneal epithelium in 1981 at the Aerospace Medical Association Meeting. In 1983, Trokel and colleagues¹⁵ showed how the excimer laser could be used to ablate bovine corneal stroma. Their study also identified an excimer laser emission of 193 nm as ideal in terms of increasing to a maximum ablation efficiency, and limiting collateral thermal damage to the surrounding collagen within the cornea. In 1985, Seiler did the first excimer laser treatment in a blind eye. He later did the first excimer laser astigmatic keratotomy.¹⁶ The first FDA trials were initiated by L'Esperance and consisted of photorefractive keratectomy in a blind eye.¹⁷ McDonald and colleagues¹⁸ then did the first photorefractive keratectomy on a seeing eye with myopia.

Jose Barraquer's pioneering work, including the use of lamellar procedures to subtract corneal stromal tissue and the development of the first microkerotomes, set the stage for laser in situ keratomileusis (LASIK) surgery.^{13,19} Ruiz and Rowsey²⁰ modified Barraquer's technique to undertake keratomileusis in situ with a geared automated microkeratome. In the early 1990s, Pallikaris and colleagues²¹ and Buratto and colleagues²² independently described a technique that combined two existing technologies: the microkeratome and the excimer laser. Pallikaris coined the term LASIK for this new technique, which has become a widely used refractive technique worldwide.

Preoperative assessment

Patients' history

The preoperative assessment for laser refractive surgery begins with careful acquisition of the patient's ophthalmic history and general medical history. In view of the elective nature of refractive surgery, the selection of appropriate surgical candidates is paramount. Active infection or intra-ocular inflammation is a contraindication for laser refractive surgery. However, surgery on patients with cured or controlled disease can be more controversial. A history of bacterial keratitis would not exclude surgery, but even a remote history of herpetic keratitis is believed by many to contraindicate laser refractive surgery, since application of the laser can potentially stimulate herpes simplex virus re-activation.²³ Most refractive surgeons hesitate to undertake laser surgery on eyes with a history of uveitis. Although not absolute contraindications to laser surgery, a history of glaucoma, retinal detachment, ocular trauma, and previous ocular surgery might affect the decision to undertake surgery or alter the surgical plan in substantial ways. For example, after central corneal excimer laser ablation, the cornea is thinned and measurements of intraocular pressure might be artifactually low. Postoperative monitoring of the intraocular pressure in glaucomatous eyes might thus become more difficult. A patient with well-controlled glaucoma might still be a candidate for refractive surgery, but a patient with severe disease should defer surgery.

With the removal of tissue by laser refractive surgical techniques, the presence of keratoconus is a strong contraindication for LASIK surgery. Creation of a lamellar flap and tissue removal can destabilise an already ectatic cornea and worsen the condition. Some researchers²⁴ have suggested that surface ablation might be acceptable in some individuals, although this issue remains controversial. Also of importance is the identification of keratoconus suspects or forme fruste keratoconus, which might be a contraindication for LASIK surgery.

A patient's lifestyle, vocation, and hobbies might also affect their selection for surgery, and the choice of vision correction modality. Participation in contact sports is a contraindication for LASIK surgery because of the risk of flap trauma. In view of the limitations of the surgery, patients who can tolerate zero risk to vision or need perfect stereopsis (and who presently have good vision and stereovision with other forms of correction) for their jobs or hobbies might not be good candidates for laser refractive procedures. The armed services has recognised that soldiers should be encouraged to pursue surface ablation instead of LASIK to avoid the risks associated with flap trauma.²⁵

A history of contact lens use and the length of time the patient has refrained from use before the assessment should be established. In general, patients should not have used soft contact lenses for at least 1 week before the assessment, and patients who wear rigid lenses should wait a minimum of 3 weeks. Even with these

guidelines, there are several examples of contact lens-induced changes in corneal shape that persist for months.²⁶

Patients should have stable refractions, and a history of frequent or recent changes in the refraction should delay surgery. Patients younger than 18 years of age might not have stable refractions, and surgery on these patients should be deferred.

Refraction

A careful refraction is a mainstay of laser refractive surgery. Although an automated refraction might serve as a useful starting point, a subjective manifest refraction must be carefully done. A hand-held retinoscope can also be used to estimate the refraction and can also identify corneal irregularities. Once the manifest refraction has been completed, the patient's ability to accommodate (focus at near) should be paralysed with a cycloplegic agent—eg, cyclopentolate 1%.

Refractions obtained by any of these methods should be compared to allow surgical planning. Consistency between measurements should be the aim, and any disparities should be explained before surgery. The degree of refractive error also helps to establish the eligibility of the patient for treatment with a particular surgical method on a specific laser platform. When possible, one should attempt to use excimer laser systems within US Food and Drug Administration (FDA)-approved treatment ranges. Refractive error outside these ranges can be treated with the laser outside of FDA approval (with informed consent from the patient), on an alternative platform with a larger approved treatment range, or only partly treated.

Measurements of corneal curvature

Keratometry can measure the steepest and flattest corneal meridians. These measurements usually correlate with the refraction unless the lens is a source of astigmatic refractive error. Corneas outside normal ranges (>47 D or <39 D) should create suspicion. The degree of cutting of lamellar flaps with a microkeratome can be altered, according to the keratometry readings.

Automated corneal topography can be done to measure the corneal curvature at multiple points across the cornea. The corneal relief map identifies the overall corneal shape. Irregularities of shape consistent with ectatic disorders, such as keratoconus and pellucid marginal degeneration, can be identified by careful analysis of these maps. Moreover, a predisposition for these disorders, forme fruste ectasia, might be identified, even when no manifest disease is seen via slit-lamp biomicroscopy.

Pachymetry

Central corneal thickness is generally measured by ultrasonic pachymetry. The removal of large amounts of corneal tissue during laser refractive surgery can lead to weakening of the cornea and ectasia, resulting in loss of

vision and surgical effect. Knowledge of the central corneal thickness provides the surgeon with an estimate of the corneal residual bed (the amount of stroma posterior to the deepest ablation). At least 250 μm (we prefer a more conservative value of 300 μm) thickness should remain at the end of the procedure to maintain the structural integrity of the cornea. The pachymetry, combined with the level of refractive error, directs the surgical planning.

Pupillometry

Pupil size under both bright and dim illumination is tested. Excimer laser ablation treatment diameters can be adjusted. The role of pupil size (especially the size relative to ablation diameter) as a risk factor for postoperative glare and halos is controversial. However, most refractive surgeons agree that pupil size, although not the only factor in glare, might play a substantial part.²⁷ When possible, an attempt to make the treatment diameter greater than the largest pupil size might reduce induced aberrations and prevent the symptoms of glare and halos postoperatively. However, for a given amount of intended correction, the larger the ablation diameter, the greater is the required treatment depth and the greater is the risk of LASIK-induced ectasia.

Tear production

Tear production and quality can be assessed by examining the tear meniscus and persistence at the slit lamp. We often undertake a Schirmer's tear production test to obtain a quantitative assessment of the amount of tear production. Dry eye syndrome is a common postoperative complication after laser refractive surgery, and treatment of any pre-existing dry eye can be important. If tear production is extremely low (as in Sjögren's syndrome) and if a patient's symptoms do not improve with appropriate treatment, the patient might benefit from deferring LASIK refractive surgery. Surface ablation might be less risky in such situations.

Complete eye examination

Further to the examination components listed above, candidates for potential refractive surgery should have other tests, including tonometry, slit-lamp biomicroscopy, motility, ocular alignment, and dilated fundus examination. Anatomical factors that could affect surgery should be identified. Glaucoma and cataract might affect the patient's candidacy for a refractive procedure, since thinning of the cornea makes intraocular pressure measurements more difficult and progressive cataract can cause the refraction to shift. Eventual cataract surgery is affected by previous laser vision correction, since predictable intraocular lens calculations are harder to measure accurately. A myriad of calculation systems that use preoperative and postoperative measurements and nomograms have been developed to help improve intraocular lens calculations after refractive surgery.

Newer modalities, such as high-frequency ultrasound, anterior segment ocular coherence tomography, and Scheimflug cameras, might improve our ability to identify changes in the anterior and posterior corneal surface relation and improve lens calculations further.

Counselling

Perhaps the greatest factor in assuring the ultimate success of laser refractive surgery is communication during the preoperative visit. Refractive surgical techniques have a high degree of objective success. Patients should be given realistic expectations as to what refractive surgery can offer and should be made aware of the risks of surgery. Several refractive surgical options available to patients, many of which do not use the excimer laser, have grown in popularity over the years. A discussion of these newer techniques and how they might apply to the specific patient, might be necessary. Patients will go to their assessment with ever more knowledge as the internet becomes a burgeoning source of medical information and misinformation. The refractive surgeon should be prepared to deal with the questions that inevitably arise from this information.

Surgical techniques

Several effective options for laser refractive surgery are available. Navigating the complex array of options can be difficult, but more choices also bring the opportunity to meet more of the needs of an individual patient. The choices can broadly be divided into lamellar (LASIK) and surface (photorefractive keratectomy, laser epithelial keratomileusis [LASEK], and Epi-LASIK) ablation.

LASIK

LASIK is lamellar laser refractive surgery in which the excimer laser ablation is done under a partial-thickness lamellar corneal flap. Until recently, the lamellar flap could only be made with a microkeratome. The microkeratome uses an oscillating blade to cut the flap after immobilisation of the cornea with a suction ring. Microkeratomes from several companies cut the lamellar flaps with either superior or nasal hinges, and can cut to depths of 100–200 µm.

A femtosecond laser has been developed that can etch lamellar flaps within the cornea stroma at a desired corneal depth. The femtosecond laser provides more accuracy in flap thickness than previous methods; the microkeratome cuts can vary widely in depth, even with the same preset thickness.²⁸

Femtosecond laser flap creation is less dependent on the corneal curvature and might be more reliable in cases of steep or flat corneas, which can be at greater risk for irregular corneal cuts. Increased cost, surgical time, and diffuse lamellar keratitis are potential limitations of the femtosecond laser keratome. The incidence and severity of diffuse lamellar keratitis are ameliorated by the use of intensive postoperative topical corticosteroids.

Once the flap has been created, it is reflected at its hinge away from the corneal stroma. The patient is asked to fixate on a centration light, an eye-tracker is engaged to adjust for any eye movements during the ablation, and a preprogrammed excimer ablation is done. Variables such as refractive target, treatment diameter, and treatment blend zone can be altered for most laser platforms. Excimer laser pulses might be applied as a variable spot scanning pattern or as a flying spot pattern. The ablation might either correct sphere and cylinder error, or be wavefront-guided. After the ablation has been completed, the stromal bed is irrigated and the corneal flap is repositioned.

Compared with surface ablation, LASIK results in earlier and faster improvement of uncorrected visual acuity, and has less (or almost no) postoperative discomfort, improved stability, and predictability. With LASIK, however, the risks of flap-related complications (wrinkles, debris, folds, buttonhole, and diffuse lamellar keratitis) may be associated with the creation of the lamellar flap.

Surface ablation

This class of laser refractive surgical procedure uses the excimer laser to ablate the most anterior portion of the corneal stroma. These procedures do not require a partial thickness cut into the stroma, and thus leave a larger residual bed to retain the cornea's biomechanical strength. The ablation of the anterior stroma and, in particular, ablation through Bowman's layer does, however, lead to a wound-healing response that might result in greater stromal haze and scarring than that in LASIK. Recovery after surface ablation is both substantially slower and more painful than that after LASIK. LASIK patients often have markedly improved vision 2–3 days after surgery and have little or no pain; patients who receive surface ablation typically have episodes of moderate to severe pain for 1–4 days after the procedure, and usually do not achieve vision similar to LASIK patients for several weeks. Several reports have shown good visual outcomes after photorefractive keratectomy for low-to-moderate hyperopia.^{29–31}

Three methods of surface ablation are in use: photorefractive keratectomy, LASEK, and Epi-LASIK. These methods differ in the way the epithelial layer is handled. In photorefractive keratectomy surgery the epithelium is removed, a large epithelial defect ensues, and healing occurs by migration and division of surrounding epithelium. The epithelium might be removed in several ways, including excimer laser destruction, mechanical debridement with a surgical blade, abrasion with a brush, or use of alcohol to loosen the epithelium.

In LASEK and Epi-LASIK surgery, the patient's original epithelial sheet is repositioned onto the stromal bed after laser ablation. After the ablation, this epithelial sheet is placed back into its original position using preplaced

corneal surface marks.³² The epithelial alignment is protected from blinks and eye movements by the addition of a bandage contact lens. A series of techniques have been developed, each differing slightly in the way in which the flap is chemically loosened and then reflected away from the cornea. In Epi-LASIK, a purely mechanical means of epithelial dissection allows the creation of an epithelial sheet, which is repositioned on the stroma after excimer laser ablation. Several epikeratomes have been developed for this purpose. These devices differ from LASIK microkeratomes in that the blade and its angle of cutting are optimised for a clean subepithelial dissection, which does not disrupt the corneal stroma.³³

Whether the outcomes of photorefractive keratectomy, LASEK, and Epi-LASIK actually differ is unclear, in part because the viability of the replaced epithelial sheet is uncertain. 6 months after surgery, the procedures have very similar outcomes with respect to acuity and refractive error. It is tempting to hypothesise that if the epithelium is viable, it might serve to quell some of the pain experienced as a result of the epithelial defect. The biological properties of the epithelium might also modulate corneal wound healing, and inhibit haze formation after surgery. Laboratory data suggest that not only is the epithelium viable after carefully controlled epithelial lifting, but that cell death in keratocytes below the treatment might be reduced in LASEK as compared with photorefractive keratectomy.³⁴

Conventional versus wavefront-guided treatment

Whether the surgeon does LASIK or surface ablation, the “Where?” in laser refractive surgery is decided. With the advent of wavefront aberrometry and lasers capable of translating these data into ablation profiles, we now have a choice in “How?” the laser surgery will be done. Conventional ablations make use of data obtained during manifest and cycloplegic refractions. The ablation profile will contain a spherical component and an astigmatic component when applicable. Although the profiles incorporate additional nomogram adjustments and additional components for blending the transition zone between the treated and untreated stroma, they essentially treat what glasses have been treating for hundreds of years.

Wavefront-guided treatments allow optical properties beyond spherical and cylindrical defocus to be corrected. Wavefront aberrometers capture data that describe the optical aberrations of a patient’s eye as an optical system.^{35,36} These measurements take into account factors beyond corneal irregularities. Aberrations from other sources, however, can be corrected at the corneal plane by the excimer laser guided by the wavefront data. Preoperative analysis of higher-order aberrations (those beyond defocus corrected by glasses) can be done preoperatively and quantified. Whether the degree of higher-order wavefront aberrations should be the determinant for a particular eye to receive wavefront-

guided ablation is still unclear. Refractive surgery itself produces higher-order aberrations, and it can be argued that even in the patient with a perfect preoperative wavefront, wavefront-guided treatment should be done to prevent the inevitable increase of aberrations caused by the procedure. Since wavefront-guided treatments correct more components, it is not surprising that for a given eye the wavefront-guided treatment will ablate deeper into the stroma. The increased depth of these ablations might hinder their use in higher myopia or patients with thin corneas (patients who might have a great deal of higher-order aberrations).

The effectiveness of custom treatments to correct aberrations after previous surgery is also not well established. In theory, affected patients might benefit most from a wavefront-guided enhancement. In practice, however, whether the algorithms used to translate the aberrometry data into ablation profiles have been optimised for enhancements, particularly when the aberrations are caused by previous, often complicated refractive surgery, is unclear.

Outcomes of laser eye surgery

Outcome data are available from multiple sources, including the FDA, laser-producing companies, and independent investigators. The number of patients, outcome measures, and length of follow-up might differ in these sources, making data comparison somewhat problematic. For this review, we have divided the available data into two groups: data obtained from the FDA clinical trial database of laser platforms,^{37–49} and other data from laser companies or individual investigators.^{50–66} FDA data are derived from well controlled and monitored investigations of outcomes in a large cohort of patients and are rigorously analysed. We grouped data from multiple FDA studies for myopia into four subgroups—0 to –2 D, –2 D to –4 D, –4 D to –7 D, and –7 D to –12 D—and those for hyperopia into three subgroups—0 to +2 D, +2 D to +4 D, and +4 D to +6 D. The cut-off points were included in the corresponding subgroups on the basis of the subdivisions within the individual FDA applications. The other sources of data varied substantially in methodology and level of analysis. Follow-up times for these other sources of data were often insufficient to accurately show reasonably final surgical outcomes.

Most published analyses of data have pitted laser platform against laser platform. This head-to-head comparison of laser platforms in published work might be driven in part by marketing concerns. We have grouped data for different treatment modalities (conventional *vs* wavefront-guided treatments) and for every type of refractive error treated (low or moderate myopia *vs* high myopia *vs* hyperopia), when sufficient data for comparison were available. In this way, we were able to assess the effectiveness of laser refractive techniques, and not just how well a particular laser works.

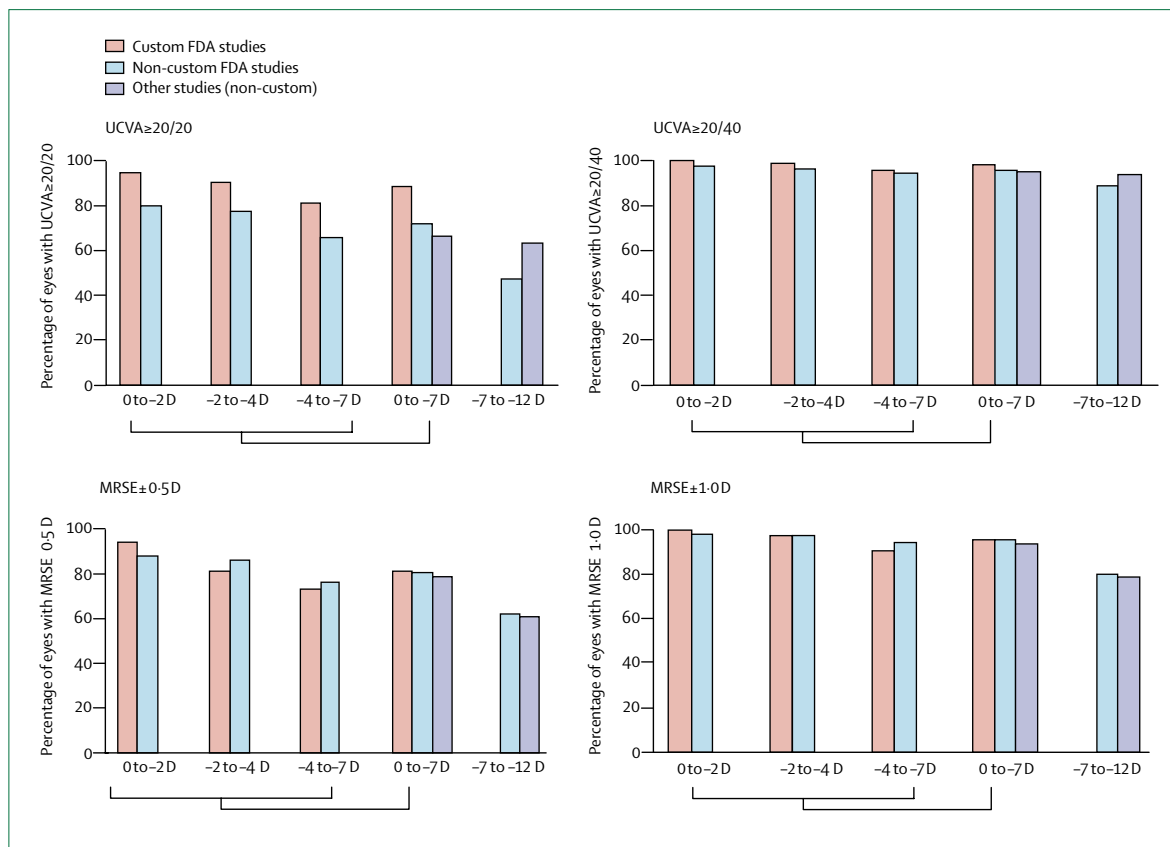


Figure 1: Visual outcomes of LASIK for myopia at 3–6 months after surgery

UCV A=uncorrected visual acuity. MRSE=manifest refraction spherical equivalents. For every assessment, results for low myopia with error 0 to -7 D (individual ranges and grouped) compared with high myopia with refractive error -7 D to -12 D.^{37–45, 50–61}

We compared a combination of measures of refraction and visual acuity. Fortunately, these variables are primary outcomes in almost all studies of laser vision correction. Manifest refraction spherical equivalent is the amount of refractive error that remains after ablation, and combines both the spherical and astigmatic correction. Manifest refraction spherical equivalent thus measures the ability of the laser refractive procedure to reach the target refraction. We analysed postoperative manifest refractive spherical equivalents to determine the percentage of patients whose residual refractive error fell within about 0.50 D or about 1.0 D of the target error. Visual acuity is a subjective measure of the patient's ability to resolve objects (usually letters) at under defined lighting conditions. Although this measure does not necessarily replace the patient's visual function in his or her environment, it does provide a standardised way to assess the success of the procedure. The number of patients with uncorrected visual acuities of 20/20 (normal perfect vision) or more and of 20/40 (functional vision usually allowing the patient to drive without glasses) or more was analysed in this review. A loss of best spectacle-corrected visual acuity of more than two

lines on the Snellen chart was used to measure negative outcomes for the procedures. Our results are shown in figures 1–3. Published results were obtained by the following criteria: (1) randomised prospective study ($n \geq 25$, follow-up period ≥ 3 months), (2) controlled prospective study ($n \geq 50$, follow-up period ≥ 3 months), and (3) case series ($n \geq 100$, follow-up period ≥ 6 months). However, it should be noted that even though the Snellen chart-based visual acuity has been judged as the standard method of assessing the outcomes of ophthalmic surgery, the variables mentioned above might not be enough to assess the satisfactory functional visual outcomes after refractive surgery. Laser refractive surgery can cause higher-order aberrations, such as glare, halo, or night-vision disturbance, and other variables such as contrast sensitivity, and scotopic and mesopic vision. Wavefront aberrometers will probably have a greater role in measuring outcomes.

LASIK outcomes

Low to moderate myopia (conventional laser ablation)

Those with low (-4 D or less) or moderate (-4 D to -7 D) myopia represent the largest population of patients undergoing laser refractive surgery. They represent the

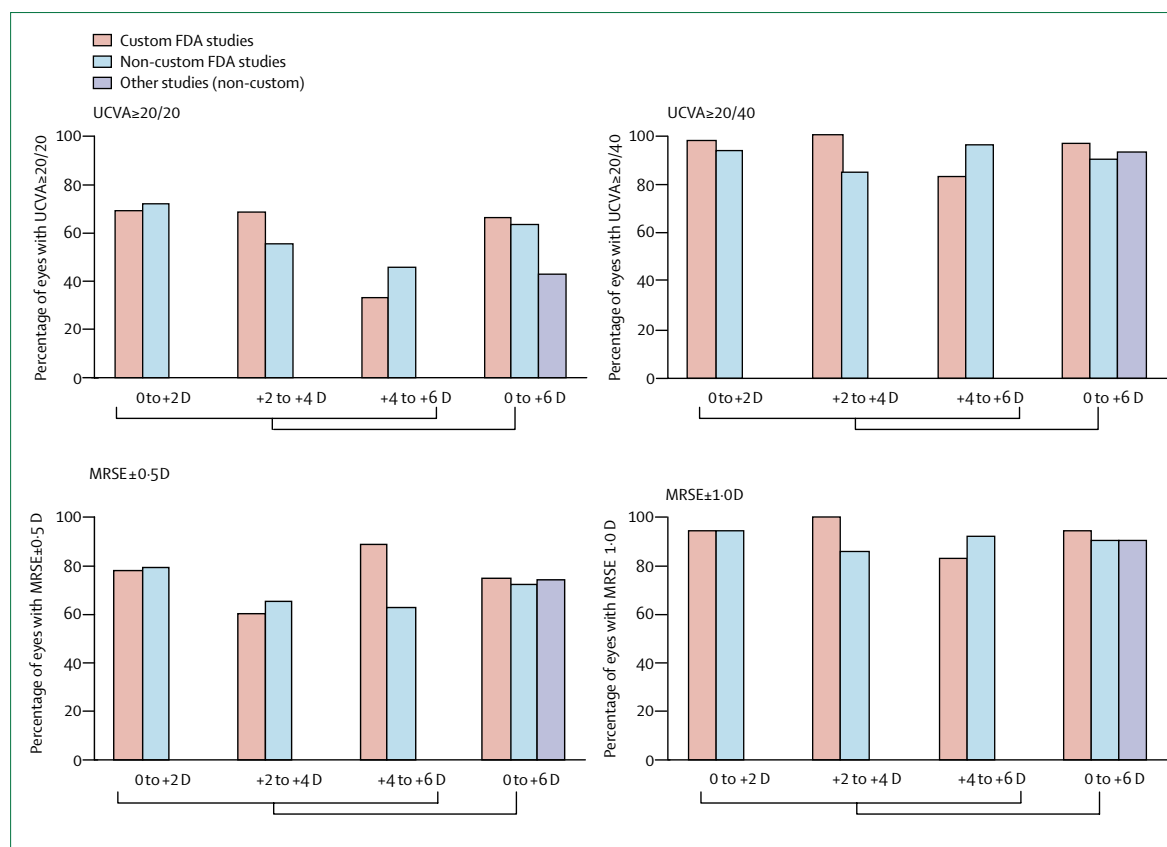


Figure 2: Visual outcomes of LASIK studies for hyperopia

UCVA=uncorrected visual acuity. MRSE=manifest refraction spherical equivalents. Data analysed for different degrees of hyperopia and for all hyperopia.^{46-49,62-66}

largest proportion of the general population; also, patients with higher myopia might not qualify as candidates for laser surgery. In view of the preponderance of low to moderate myopia, it is not surprising that the first FDA-approved use of the excimer laser for LASIK was for these patients.

Grouped data from the FDA-approved laser platforms (LADAR Vision, Alcon, Fort Worth, TX, USA; EC5000, NIDEK, Gamagori, Japan; S2 & S3, VISX, Santa Clara, CA, USA; Technolas 217a, Bausch & Lomb, Rochester, NY, USA; Allegretto Wave, WaveLight, Sterling, VA, USA)³⁷⁻⁴² for low to moderate myopia showed manifest refraction spherical equivalent within about 1.00 D of 96% and within about 0.50 D of 81%. Similarly, uncorrected visual acuities better than 20/40 were measured in 96%, although 72% of patients had vision equal to or better than 20/20. A loss of best spectacle-corrected visual acuity of more than two lines was noted in just under 1.0% of patients.

Comparison of the FDA data with other studies revealed similar outcomes with respect to efficacy. Combined data from the non-FDA dataset show manifest refraction spherical equivalent within about 1.00 D of 94% and within about 0.50 D of 79%. About 95% of patients were 20/40 or better and 67% were

20/20 or better uncorrected. These other studies did, however, have a higher rate of best spectacle-corrected visual acuity loss totalling more than 2.3%. These overall excellent success rates explain the popularity of laser refractive surgery.

High myopia (conventional laser ablation)

With the larger degree of refractive error and the concomitant need to remove more tissue in higher myopia, this group of patients is often analysed separately when measuring outcomes of refractive surgery. In the high myopia group, FDA data showed manifest refraction spherical equivalent within about 1.00 D of 80% and within about 0.50 D of 61%. Although 89% of patients were 20/40 or better, less than half (48%) achieved 20/20 or better. A loss of best spectacle-corrected visual acuity of greater than two lines was recorded in only 1% of patients.

Similarly, combined data from the non-FDA dataset showed manifest refraction spherical equivalent within about 1.00 D of 79% and within about 0.50 D of 59%. 94% of patients were 20/40 or better; 64% were 20/20 or better. Compared with FDA data, a loss of best spectacle-corrected visual acuity of more than two lines was noted in a higher rate of 2% of patients.

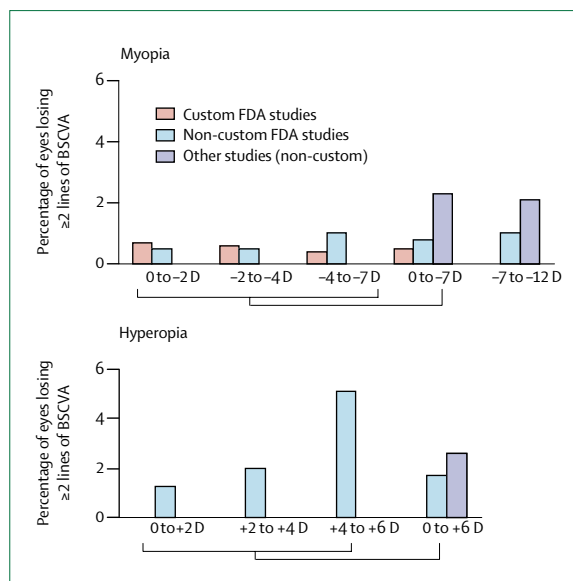


Figure 3: Safety of LASIK for treatment of myopia or hyperopia
BSCVA=best spectacle-corrected visual acuity.^{37-49,51,52,55-66}

Comparison of low to moderate versus high myopia

In general, we might expect less accuracy and larger wound-healing effects with the deeper ablations. As the depth decreases, the cornea might also be destabilised, and this instability can further retard the ability to reach a target refraction. With the FDA data, a comparison of manifest refraction spherical equivalent between low-to-moderate and high myopia after LASIK shows a larger residual refractive error in high myopia. The difference between the low-to-moderate myopia of 96% within about 1.00 D and high myopia with 80% was even more indicative when accuracy to within manifest refraction spherical equivalent of about 0.50 D was analysed (81% for the lower myopic group and 61% for the higher myopic group).

This trend was also noted in the analysis of FDA data on final uncorrected visual acuities. For the less myopic group, acuity of at least 20/40 was achieved in 96% of patients as compared with only 89% of the high myopia group. Again, the difference is even more pronounced when better acuities are examined. Less than half (48%) of patients with high myopia achieved acuities of 20/20 or better with LASIK; however, almost 72% of lower myopia achieved this excellent acuity level. Similar analysis of non-FDA data provided similar outcomes.

The cut-off point between low-to-moderate and high myopia has been used in published work as a distinction, but these degrees of myopia are somewhat arbitrary. In a subgroup analysis of the FDA data, we noted that correlation between the degree of initial refractive error and the level of residual myopia and poorer acuity was fairly linear, even with the low-to-moderate group. In general, patients with higher degrees of myopia should be told that their likelihood of reaching perfect vision is less than in patients with lower myopia.

The rate of best spectacle-corrected visual acuity loss was essentially the same for all myopic groups. This finding suggests that although the improvement in vision and refractive error might be less for high myopes, the procedure is still likely quite safe in this group. Long-term studies are needed to ascertain the true risk for the high myopes who undergo greater tissue removal. This greater tissue removal might be expected to destabilise the cornea and allow for ectasia and worsening of outcome in susceptible individuals. Data collected at 10-year or 20-year follow-up would allow for a better analysis of this potential occurrence.

Wavefront-guided LASIK (custom laser ablation) for myopia

Wavefront aberrometers represent a major advance in our ability to measure subtle, yet visually substantial, optical defects. The outcomes for wavefront-guided LASIK in myopia have been investigated by the FDA for three separate laser platforms. In view of the fewer numbers of non-FDA studies, the differing outcome measurements, and follow-up for these studies, only the FDA data are presented here.

Grouped data from the FDA-approved wavefront-guided laser platforms (LADAR Vision; Technolas 217z; and Star S4 and Wavescan Wavefront System, VISX, Santa Clara, CA, USA, and Bausch & Lomb Technolas 217z)⁴³⁻⁴⁵ for low to moderate myopia showed manifest refraction spherical equivalent within about 1.00 D in 96% of eyes and within within 0.50 D in 81%. Uncorrected visual acuities better than 20/40 were measured in 98%, and 89% of patients had vision equal to or better than 20/20. A loss of best spectacle-corrected visual acuity of more than two lines was recorded in only 0.5% of patients. Wavefront-guided LASIK seems to be most successful in patients who have low myopia, especially for uncorrected visual acuities better than 20/20. 95% of the patients up to -2 D achieved 20/20 or better, as did 91% in the range -2 to -4 D.

Comparison of wavefront-guided versus conventional laser ablation for myopia

Whether the additional information obtained with wavefront-guided treatments is translated into better ablations and improved acuity compared with conventional LASIK can be determined by comparing the FDA trials data. A marked difference in uncorrected visual acuities of 20/20 or better was seen between wavefront-guided and conventional treatments. In wavefront-guided LASIK, 89% of patients achieved this level of vision. By contrast, with conventional treatment, patients reached 20/20 or better only 72% of the time. These differences were not seen with the 20/40 or better acuity outcome.

There are no substantial differences in postoperative manifest refraction spherical equivalent between conventional and custom treatments. How can one reconcile the similar refractive outcomes in both treatments with the

better uncorrected visual acuities outcomes for wavefront-guided treatments? It cannot be certain, but the manifest refraction spherical equivalent measures only spherical and astigmatic error (defocus), which is probably similar in both treatments. The higher-order aberrations, however, are treated in wavefront-guided treatments such that these aberrations are reduced to a minimum (or the rise caused by refractive surgery is ameliorated). The improved acuity is likely explained by the higher number of aberrations remaining after conventional treatments.

Some care should be taken when comparing the FDA data between wavefront-guided and conventional treatments. The data for conventional treatments were gathered with earlier generation laser platforms. Since FDA approval, improvements have been made to the lasers, the software driving the lasers, the laser-tracking devices, and our ability to identify patients who are poor candidates for LASIK. These improvements are unrelated to wavefront technology. The assessment of specific laser platforms is not the purpose of this review, but a current generation laser system (Allegretto Wavelight), which incorporates technological advances unrelated to custom ablation was approved by the FDA in 2003. Treatment results are better than seen with the older generations of laser, though still not as good as those seen with the wavefront-guided lasers in terms of final uncorrected visual acuities. The Allegretto system is wavefront optimised, in that the rise in higher-order aberrations seen after laser vision correction is reduced to a minimum by the ablation algorithm. By contrast with truly wavefront-guided systems, which use actual wavefront data obtained from the eye to be treated, wavefront-optimised systems adjust the ablation profile without actually measuring higher-order aberrations in the patient.

Hyperopia

For hyperopic LASIK ablations, most of the laser energy is directed at the periphery of the treatment zone with a relative sparing of the central cornea. Centration and tracking are essential factors in obtaining accurate ablations without inducing astigmatism from decentration. Additionally, mechanical weakening of the peripheral cornea might allow the central cornea to bow forward, augmenting the intended laser effect. Wound healing from hyperopic treatments also seems to differ from myopic treatments. The biomechanical changes and the wound healing in hyperopic LASIK cause increased levels of regression after this procedure and limit the total refractive error that can be treated with the LASIK technique.

Grouped data from the FDA approved non-custom laser platforms (Alcon LADAR, VISX S2 & S3, Bausch & Lomb Technolas 217a, and Allegretto Wave Wavelight) showed manifest refraction spherical equivalent within about 1.00 D of 90% and within about 0.50 D of 67%.⁴⁶⁻⁴⁸ Similarly, uncorrected visual acuities better than 20/40 were measured in 90%, although 63% of patients had vision

equal to or better than 20/20. A loss of best spectacle-corrected visual acuity of more than two lines was recorded in just under 2% of patients. Data for non-FDA studies differed substantially from the FDA studies in the proportion of patients achieving 20/20 or better vision.⁶²⁻⁶⁶ This lower level of acuity is noted despite a similar degree of manifest refraction spherical equivalent about 0.50 D in both types of studies. The basis of this difference is not clear.

In FDA-approved custom laser platform (VISX Star S4 & Wavelight Wavefront System),⁴⁹ manifest refraction spherical equivalent within about 1.00 D was 95% and within about 0.50 D was 70%. Similarly, uncorrected visual acuities better than 20/40 were measured in 97%, and 66% of patients had vision equal to or better than 20/20. A loss of best spectacle-corrected visual acuity of more than two lines was recorded in 0% of patients.

Unlike the custom versus conventional myopic treatments, it is difficult to draw conclusions on the basis of the comparison between this custom FDA study and non-custom FDA studies for 0 to +6 D hyperopia. For the lower outcome standards (manifest refraction spherical equivalent about 1.00 D and best spectacle-corrected visual acuity of 20/40 or more) the wavefront-guided treatments did show a modest improvement versus the conventional treatments. However, for manifest refraction spherical equivalent about 0.50 D and best spectacle-corrected visual acuity of 20/20 or better, the two types of treatments were equivalent. This finding suggests that although wavefront-guided treatments might prevent some worse outcomes, they do not improve the chances of obtaining the best outcomes. The problems of unpredictable wound healing and biomechanics, which are important determinants in the outcome of hyperopic LASIK, are not necessarily solved by the custom ablation.

Outcomes of LASIK for mixed astigmatism

There are fewer reports available for the LASIK treatment of mixed astigmatism (the refractive condition in which rays of light in one meridian are focused in front of the eye as in myopia and rays of light in the meridian 90° away are focused behind the retina as in hyperopia) than for other problems, probably because there are fewer patients in this group overall, fewer patients in this category elect to have refractive surgery (their preoperative manifest refraction spherical equivalent can often approach zero), and fewer laser systems are approved for the treatment of this refractive condition.⁶⁷⁻⁷⁰ Patients who do have mixed astigmatism and elect to have treatment have a higher degree of cylinder (poorer acuity than would be expected on the basis of the manifest refraction spherical equivalent alone), and patients with higher levels of astigmatism tend to have less predictable outcomes.

FDA trials for LASIK-treated mixed astigmatism show an improvement in uncorrected visual acuities.⁷¹ Uncorrected visual acuities better than 20/40 were measured in 95%, and 61% of patients had vision equal to

or better than 20/20. A loss of best spectacle-corrected visual acuity of more than two lines was recorded in 0% of patients.

Outcomes of LASIK for presbyopia

Presbyopia is an age-related refractive condition in which the eye is no longer able to focus over a broad enough range to allow for both functional near and distance vision. Laser vision correction is unable to correct this condition per se, but can be harnessed to create corneal multifocality and pseudoaccommodation. Attempts to create multifocal corneas using new ablation profiles during LASIK surgery are under investigation in France and South America,^{72,73} and hold promise as future techniques to treat presbyopia.

LASIK surgery can, however, treat the symptoms of presbyopia through the use of a technique termed monovision.^{74–76} In monovision, the distance refraction for one eye is emmetropic and the distance correction for the second eye is myopic; one eye is set for distance vision and the other for nearer vision. In phakic patients who still have some degree of accommodation, albeit insufficient for their needs, the near eye need not be corrected (or left untreated) at a level of myopia for near alone (about –2.75 D), but instead can be only mildly near-sighted. The outcomes for monovision treatment are dependent not only on the ability of the laser to accurately reach the target refraction, but also on the patient's ability to adjust to anisometropia and the slight decrement in visual acuity and depth perception that arises from the different focal points in each eye. Therefore, the preoperative use of monovision contact lenses might be useful.

There are no FDA trials for the use of LASIK for monovision. Non-FDA data suggest that about 80% of patients will make the adjustment to monovision, and that most patients will adapt to monovision within 3–4 weeks. Perhaps the most important factor for obtaining good outcomes with this technique is proper selection of patients and adequate counselling before the procedure. Patients must understand that improved functional vision, if it does arise, will come only after the adaptation period, and that it comes at some price to both near and distance acuity. When the patient is unhappy,

the undercorrected eye can undergo either enhancement (re-treatment) or initial treatment (when the myopic eye was untreated) to balance the eyes. The patient will then need to use reading glasses for near tasks.

Outcomes of surface ablations (photorefractive keratectomy and LASEK)

Surface ablation (photorefractive keratectomy) was the first ablative refractive surgical technique approved by the FDA. Although photorefractive keratectomy came into some disfavour during the late 1990s, surface ablation has seen a partial resurgence for the treatment of refractive error in patients with thinner corneas and low to moderate myopia, as a result of the avoidance of lamellar flap creation and its associated risks. The improvements in the laser systems can also improve outcomes achieved by surface ablation. The LASEK procedure represents a modification of the original photorefractive keratectomy procedure in which the patient's epithelium is retained (by making an epithelial flap) instead of removed.

The original FDA studies for photorefractive keratectomy were undertaken in 1995,⁷⁷ and used laser systems that did not have capabilities of lasers today—eg, advanced software, accurate eye-tracking, and larger ablation zones. In view of the limitations of the lasers used in these studies, analysis of the FDA data alone for photorefractive keratectomy is not likely to yield useful results for today's patients. No FDA trial for the LASEK procedure has been done.

The available data suggest that surface ablation achieves results similar to LASIK. Table 1 provides cumulative data for photorefractive keratectomy and LASEK techniques.^{30,50–52,56,57,78–91} Combining all myopia, photorefractive keratectomy achieves best spectacle-corrected visual acuity of 20/20 or more in 61% of patients and of 20/40 or more in 94%, and LASEK achieves best spectacle-corrected visual acuity of 20/20 or more in 74% of patients and of 20/40 or more in 94%. For manifest refraction spherical equivalent, photorefractive keratectomy has a postoperative value of about 0.50 D in 71% of cases and LASEK in 74% of cases. From a refractive standpoint, the techniques seem very similar.

	Myopia		Hyperopia	
	PRK ^{30,50–52,56,57,78–85}	LASEK ^{78,79,85–88}	PRK ^{30,89–91}	LASEK ⁸⁹
Visual range	–1 to –13.0 D	–1 to –12.5 D	+1 to +5 D	+2 to +5 D
UCVA =20/20	2559/4184 (61.1%)	471/637 (73.9%)	474/630 (75.2%)	79/108 (73.1%)
UCVA =20/40	3877/4112 (94.3%)	361/382 (94.5%)	594/682 (87.1%)	98/108 (90.7%)
Within about 0.5 D of MRSE	2965/4158 (71.3%)	451/610 (73.9%)	481/682 (70.5%)	82/108 (75.9%)
Within about 1.0 D of MRSE	3748/4158 (90.1%)	482/538 (89.6%)	581/682 (85.2%)	99/108 (91.7%)
Loss of =two lines of BCVA	3/517 (0.6%)	13/610 (2.1%)	14/682 (2.1%)	0/108 (0.0%)

UCVA=uncorrected visual acuity. MRSE=manifest refraction spherical equivalent. BCVA=best spectacle-corrected visual acuity. Data are number (%) unless otherwise indicated. For PRK studies, data published after January, 2000, only were collected.

Table 1: Cumulated outcomes of photorefractive keratectomy (PRK) and LASEK for myopia and hyperopia

In comparative studies, LASIK and surface ablation have similar outcomes. The lower values for best spectacle-corrected visual acuity and manifest refraction spherical equivalent listed above for the surface ablation techniques might be the result of inclusion of high myopia. These higher myopia treatments, as discussed in the LASIK outcomes section, in general have poorer and less predictable results. Deep ablations for high myopia via surface ablation also have a greater tendency to produce stromal haze during the wound-healing process and thus might lead to poorer results. Indeed, most surgeons prefer not to do surface ablations in higher myopia; when they do treat these patients on the surface, they often use wound-healing biomodulators such as mitomycin C. We advise caution in using these biomodulators, since each has its own complications, and the long-term sequelae of their use for refractive surgery are not well understood. Indeed, evidence suggests the loss of stromal keratocytes after application of mitomycin C.⁹²

Complications and management

Serious complications from refractive surgery are rare, as evidenced by the low rate of loss of best spectacle-corrected visual acuity. However, as with any surgery, complications might occur either intraoperatively or postoperatively.⁹³ Risk-benefit calculations of surgery are somewhat different for refractive surgery, since procedures are generally done electively in healthy eyes with excellent visual potential.

Intraoperative complications

The creation of an intralamellar flap during the LASIK procedure increases the risk of intraoperative complications. The complications of LASIK are listed in table 2.^{94–116} In general, difficulties associated with intraoperative flaps arise because of issues related to microkeratome function—eg, malfunctions of the microkeratome assembly (loss of suction, poor blade oscillation, or interruption of keratome movement) or abnormally steep (button-hole formation) or flat (free-cap) patient cornea. The femtosecond laser has fewer problems in terms of creating irregular cuts, and managing irregular cuts created with the laser is less difficult. However, femtosecond laser has the potential to induce diffuse lamellar keratitis. Use of topical corticosteroids keeps the incidence and severity of diffuse lamellar keratitis to a manageable level. Depending on the severity and type of complication associated with flap creation, a surgeon can either ablate the cornea as planned or abort the procedure with the possibility of a future surface ablation.

For surface ablation, intraoperative complications are rare, and complications that do arise are usually not serious. If a LASEK epithelial sheet is torn or deranged, the procedure can revert to photorefractive keratectomy.

Postoperative complications

Dry eye is the most frequent complication after refractive surgery, particularly in LASIK surgery, in which the

corneal nerves are severed during the creation of the flap. Re-innervation in the subepithelial and anterior stroma is reduced by almost half, even 3 years after LASIK.¹¹⁷ The condition is often transient and tends to improve over weeks to months. For symptomatic patients, topical treatments—such as artificial tears—are used and punctal occlusion, a procedure whereby a plug is inserted in the lacrimal punctum to reduce tear outflow from the ocular surface to the nose via the lacrimal drainage system, is done for more severe cases.

The LASIK flap re-adheres initially as a result of deturgescence of the cornea, but actual collagen deposition and wound healing is quite slow (this, in part, allows the cornea to remain free from scarring). As such, the flap might be displaced in the days, weeks, or even months after the procedure. The risk of flap slippage is greatest in the immediate postoperative period, and can be caused by eye rubbing or lid squeezing. After several months, a substantial shearing force with a vector tangential to the ocular surface is usually needed to displace a flap. Displaced flaps should be lifted and irrigated, and striae should be ironed out.

Epithelial ingrowth into the lamellar interface might occur if the flap edge is not well opposed. The ingrowth has the potential to reduce visual acuity and cause melting of the stroma as a result of enzymes secreted from the epithelial cells. If epithelial ingrowth occurs in the visual axis, or signs of stroma melting are noticed, irrigation and scraping of the flap interface should be done.

Postoperative scarring and haze is more common after surface ablation than LASIK, particularly in deeper ablations for higher degrees of myopia. Often a fine reticular haze can be seen at the slit lamp, but there are no visual consequences. Visually pronounced haze might occur in 1–2% of patients with high myopia. This haze

	FDA trials*	Non-FDA studies†
Epithelial defect ^{94–98}	0.50%	5.0–22.6%
Lamellar keratitis ^{99–105}	0.99%	0.2–3.2%
Haze ^{99,106,107}	0.57%	1.8–6.2%
Flap folds ^{99,100}	1.00%	0.2–1.1%
Thin flap ^{99,100,108}	0.42%	0.08–0.75%
Free-cap ^{99,100,108}	3.40%	0.08–1.00%
Irregular flap ^{99,100}	n/a	0.09–0.2%
Buttonholed flap ^{99,100,108}	n/a	0.13–0.56%
Incomplete flap ^{99,100,108}	n/a	0.23–0.75%
Dislodged flap ^{99,100}	0.22%	1.1–2.0%
Epithelial ingrowth ^{99,100,109–111}	0.14%	0.33–9.1%
Debris ^{106,112,113}	3.31%	1.9–100%
Infectious keratitis ^{100,107,114,116}	0.0%	0.0–2%
Ectasia ¹¹⁶	0.0%	0.2%

n/a=not available. *Include studies of wavefront-guided LASIK for myopia, LASIK for myopia, and LASIK for hyperopia. †Include complications reported in studies of 1000 people or more and in reports focusing on specific complications. Data are proportion of patients affected.

Table 2: LASIK complications

can be treated by either intraoperative or postoperative application of mitomycin C or transforming growth factor- β .^{118,119}

Infection is uncommon since patients are kept on broad-spectrum antibiotics for a week after surgery. The relatively protected intralamellar space created during LASIK, however, does represent a potential haven for pathogens implanted at the time of surgery. Although many LASIK infections are caused by typical flora found on the ocular surface and lids, there is a greater incidence of keratitis caused by atypical organisms, such as mycobacterium and fungi.¹¹⁴ Treatment can consist of topical antibiotics, but the flap might also need to be lifted and the corneal bed and flap irrigated with antibiotics. Infections after surface ablation are extremely uncommon and are generally well treated with broad-spectrum topical antibiotics after culture and removal of bandage contact lenses.

Diffuse lamellar keratitis is a clinical condition characterised by collections of white blood cells within the flap interface. The cause of this inflammation is not known, but it might be a result of immune reactions to antigens within the interface or because of trauma at the time of surgery. Diffuse lamellar keratitis is more common after the use of the femtosecond laser to create the flap. In slit-lamp examinations, diffuse lamellar keratitis is noted as a wide interface, extending or confining infiltration in the early stages after the operation. If this complication is resistant to intensive topical anti-inflammatory treatment, flap lifting and irrigation should be considered.¹⁰³

Undercorrection is frequent with primary LASIK, and overcorrection is often noted after re-treatments (so-called enhancement). If the laser equipment's nomogram is not yet stabilised, especially at the beginning of use, those unexpected corrections will occur. To treat undercorrection, enhancement is needed.

Regression is defined as a return toward the original refractive error 3–6 months after refractive surgery. It was a frequent complication with the previous generation of refractive surgeries, such as radial keratotomy and photorefractive keratectomy, but seems to arise infrequently after myopic LASIK. However, regression is reported at much higher rates in hyperopic LASIK.

Halo and glare are frequent complications after refractive surgery, particularly if the patient has large pupils or if a small ablation diameter was used. These symptoms are most noticeable at night or in dark places when the pupil dilates and more light rays enter the eye through the untreated peripheral cornea. Fortunately, despite a high rate of glare and halos immediately after surgery, these symptoms usually dissipate over time. Now that we can take wavefront measurements, higher-order wavefront aberrations are increasingly blamed. In the past, symptoms were treated with a topical miotic or tinted contact lens with an artificial pupil. Currently, attention has turned to wavefront-guided enhancement surgery as a means to solve severe glare and halos.

Corneal ectasia is a dreaded late-onset complication after laser refractive surgery. In this progressive condition, the cornea bows anteriorly, creating myopia and astigmatism. The cause of postsurgical ectasia is probably loss of biomechanical stability after excessive ablation of a normal cornea (leaving a residual corneal bed of less than 250 μ m) or a reasonable ablation of a cornea, which is predisposed to corneal ectasia (most common forme fruste keratoconus). This complication's average onset is 12–14 months after LASIK.¹¹⁶ According to the few available long-term reports, the incidence of post-LASIK ectasia is low.¹¹⁶ An increasing awareness of the rate of ectasia and better ways to detect abnormal corneas before surgery should keep the rates low. Management of this severe complication might include hard gas-permeable contact lens wear, intracorneal ring segments, or keratoplasty. Soft contact lenses are not suitable because they cannot correct the irregular astigmatism.

Conclusions and future directions

Laser refractive surgery is currently the mainstay of refractive surgery. Over the past decade, millions of individuals worldwide have reduced their dependence on spectacles and contact lenses because of the success of LASIK and surface ablation. Advances in these procedures continue to make the procedures not only more effective, but also safer. The excimer laser will continue to be a primary means of refractive surgery, even as phakic and accommodative intra-ocular lenses assume a larger share of refractive surgery.

The advances in laser refractive surgery will continue to be driven by the available technology. Improvements in laser design, eye-tracking, and laser algorithms have all been incremental improvements in laser refractive surgery. The advent of wavefront-guided surgery has been in many ways revolutionary. Future work will identify which components of the wavefront map are important in providing good vision. Even more importantly, the ability of laser algorithms to effectively treat these aberrations both for primary and secondary ablations will need to be improved.

An excimer laser can precisely do ablations, yet the refractive outcomes after surgery are not always so accurate. A better understanding of the role of wound healing in the final refractive outcomes is needed. We await biomodulators of wound healing that allow for more precise refractive outcomes.

The combination of multiple refractive surgery modalities is termed bioptics (this term was coined by Roberto Zaldivar) and can allow surgeons to avail themselves of the benefits of each procedure, and at the same time reduce to a minimum the known liabilities and limitations.¹²⁰ We will probably see laser refractive surgery increasingly combined with other modes of refractive surgery, such as phakic and accommodative intra-ocular lens. Refractive surgery will be seen not as a single procedure for a single problem, but rather as a set

of refractive procedures to treat the overall vision requirements of a particular patient.

Conflict of interest statement

Dimitri T Azar is a consultant for Bausch and Lomb and Thermal Vision and has received travel support from Intralase, Alcon, Allergan/AMO, Santen, and VISX. The other authors declare that they have no conflicts of interest.

Funding sources and roles

This study was supported by a Grant EY10101 from the National Eye Institute (DTA), the Research to Prevent Blindness Lew Wasserman Fund (DTA), the Bausch and Lomb Japan/MEEI Research Fellowship Award (TS), the Japan Eye Bank Association (TS), and the MEEI/SERI Joint Clinical Research Center Fellowship (MIR). These funding sources provide research support for the authors, but have no affiliation with any company or product.

References

- Waring GO, 3rd. Corneal structure and pathophysiology. In: Leibowitz H, ed. Corneal disorders. Philadelphia: WB Saunders, 1984: 3–25.
- Schwiegerling J. Theoretical limits to visual performance. *Surv Ophthalmol* 2000; **45**: 139–46.
- Maeda N. Evaluation of optical quality of corneas using corneal topographers. *Cornea* 2002; **21** (7 suppl): S75–78.
- Da Vinci L. Codex of the eye. *Manuscript D*, circa 1508.
- Donders FC. On the anomalies of accommodation and refraction of the eye. London: The Hatton Press for the Sydenham Society, 1864.
- Schiøtz HA. Ein fall von hochgradigem hornhautastigmatismus nach staarextraction: besserung auf operativem Wege. *Archiv für Augenheilkunde* 1885; **15**: 179–81.
- Faber E. Operative behandeling von astigmatisme. *Nederl Tijdschr Geneesk* 1895; **31**: 495–96.
- Lucciola J. Traitement chirurgical de l'astigmatisme. *Arch Ophthalmol* 1886; **16**: 630–38.
- Lans L. Experimentelle untersuchungen über entstehung von astigmatismus durch nicht perforierende corneawunden. *Arch Ophthalmol* 1898; **45**: 117–52.
- Sato T. Crosswise incisions of Descemet's membrane for the treatment of advanced keratoconus. *Acta Soc Ophthalmol (Jpn)* 1942; **46**: 469–70.
- Durnev VV. Characteristics of surgical correction of myopia after 16 and 32 peripheral anterior radial non-perforating incisions. In: Fyodorov SN, ed. Surgery of anomalies in ocular refraction. Moscow: The Moscow Research Institute of Ocular Microsurgery, 1981: 33–35.
- Barraquer JI. Oueratoplasia refractive. *Estudios Inform* 1949; **2**: 10–21.
- Barraquer JI. Keratomileusis for the correction of myopia. *Arch Soc Am Oftal Optom* 1964; **5**: 27–48.
- Taboada J, Archibald CJ. An extreme sensitivity in the corneal epithelium to far UV-ArF excimer laser pulses. Proceedings of the Aerospace Medical Association, 52 Annual Meeting 1981, Washington, DC:8–9.
- Trokel SL, Srinivasan R, Braren B. Excimer laser surgery of the cornea. *Am J Ophthalmol* 1983; **96**: 710–15.
- Seiler T, Wollensak J. In vivo experiments with the excimer laser: technical parameters and healing processes. *Ophthalmologica* 1986; **192**: 65–70.
- L'Esperance FA Jr, Taylor DM, Del Pero RA, et al. Human excimer laser corneal surgery: preliminary report. *Trans Am Ophthalmol Soc* 1988; **86**: 208–75.
- McDonald MB, Kaufman HE, Frantz JM, Shofner S, Salmeron B, Klyce SD. Excimer laser ablation in a human eye. *Arch Ophthalmol* 1989; **107**: 641–42.
- Barraquer JI. Queratoplastia refractiva. Bogota: Instituto Barraquer de America, 1970.
- Ruiz L, Rowsey JJ. In situ keratomileusis. *Invest Ophthalmol Vis Sci* 1988; **29**: S392.
- Pallikaris IG, Papatzanaki ME, Stathi EZ, Frenschok O, Georgiadis A. Laser in situ keratomileusis. *Lasers Surg Med* 1990; **10**: 463–68.
- Buratto L, Ferrari M, Genisi C. Myopic keratomileusis with the excimer laser: one-year follow up. *Refract Corneal Surg* 1993; **9**: 12–19.
- Dhaliwal DK, Romanowski EG, Yates KA, Hu D, Goldstein M, Gordon YJ. Experimental laser-assisted in situ keratomileusis induces the reactivation of latent herpes simplex virus. *Am J Ophthalmol* 2001; **131**: 506–07.
- Kasparova EA, Kasparov AA. Six-year experience with excimer laser surgery for primary keratoconus in Russia. *J Refract Surg* 2003; **19** (suppl 2): S250–54.
- Hammond MD, Madigan WP, Bower KS. Refractive surgery in the United States Army, 2000–2003. *Ophthalmology* 2005; **112**: 184–90.
- Wilson SE, Lin DT, Klyce SD, et al. Topographic changes in contact lens-induced corneal warpage. *Ophthalmology* 1990; **97**: 734–44.
- Klyce SD. Night vision after LASIK: the pupil proclaims innocence. *Ophthalmology* 2004; **111**: 1–2.
- Kezirian GM, Stonecipher KG. Comparison of the IntraLase femtosecond laser and mechanical keratomes for laser in situ keratomileusis. *J Cataract Refract Surg* 2004; **30**: 804–11.
- Jackson WB, Casson E, Hodge WG, Mintsoulis G, Agapitos PJ. Laser vision correction for low hyperopia: an 18-month assessment of safety and efficacy. *Ophthalmology* 1998; **105**: 1727–38.
- Williams DK. One-year results of laser vision correction for low to moderate hyperopia. *Ophthalmology* 2000; **107**: 72–75.
- Nagy ZZ, Munkacsy G, Popper M. Photorefractive keratectomy using the meditec MEL 70 G-scan laser for hyperopia and hyperopic astigmatism. *J Refract Surg* 2002; **18**: 542–50.
- Taneri S, Feit R, Azar DT. Safety, efficacy, and stability indices of LASEK correction in moderate myopia and astigmatism. *J Cataract Refract Surg* 2004; **30**: 2130–37.
- Pallikaris IG, Naoumidi, II, Kalyvianaki MI, Katsanevaki VJ. Epi-LASIK: comparative histological evaluation of mechanical and alcohol-assisted epithelial separation. *J Cataract Refract Surg* 2003; **29**: 1496–501.
- Laube T, Wissing S, Theiss C, Brockmann C, Steuhl KP, Meller D. Decreased keratocyte death after laser-assisted subepithelial keratectomy and photorefractive keratectomy in rabbits. *J Cataract Refract Surg* 2004; **30**: 1998–2004.
- Yeh PC, Azar DT. Wavefront-guided custom LASIK and LASEK: techniques and outcomes. In: Foster CS, Azar DT, Dohlman CH, eds. Smolin and Thoft's the cornea. Philadelphia: Lippincott Williams & Wilkins, 2004: 1257–68.
- Yeh SI, Azar DT. The future of wavefront sensing and customization. *Ophthalmol Clin North Am* 2004; **17**: 247–60.
- US FDA. LADARVision® Excimer Laser System. P970043/S005. May 9, 2000. <http://www.fda.gov/cdrh/pdf/p970043s005.html> (accessed Nov 11, 2005).
- US FDA. TECHNOLAS® 217A Excimer Laser System. P990027. Feb 23, 2000. <http://www.fda.gov/cdrh/pdf/p990027.html> (accessed Nov 11, 2005).
- US FDA. TECHNOLAS® 217A Excimer Laser System. P990027/S2. May 17, 2002. <http://www.fda.gov/cdrh/pdf/p990027s002.html> (accessed Nov 11, 2005).
- US FDA. Nidek EC-5000 Excimer Laser System. P970053/S002. April 14, 2000. <http://www.fda.gov/cdrh/pdf/p970053s002.html> (accessed Nov 11, 2005).
- US FDA. VISX STAR S2 Excimer Laser System. P990010. Nov 19, 1999. <http://www.fda.gov/cdrh/pdf/p990010.html> (accessed Nov 11, 2005).
- US FDA. WaveLight ALLEGRETTO WAVE™ Excimer Laser System. P020050. Oct 7, 2003. <http://www.fda.gov/cdrh/PDF2/p020050.html> (accessed Nov 11, 2005).
- US FDA. LADARVision® Excimer Laser System. P970043/S10. May 9, 2000. <http://www.fda.gov/cdrh/pdf/p970043s010.html> (accessed Nov 11, 2005).
- US FDA. Bausch & Lomb TECHNOLAS® 217z Zyoptix System for Personalized Vision Correction. P990027/S006. Oct 10, 2003. <http://www.fda.gov/cdrh/pdf/p990027s006.html> (accessed Nov 11, 2005).
- US FDA. STAR S4 Active Trak™ Excimer Laser System and WaveScan Wave Front® System. P930016/S016. May 5, 2003. <http://www.fda.gov/cdrh/pdf/p930016s016.html> (accessed Nov 11, 2005).
- US FDA. TECHNOLAS® 217A Excimer Laser System. P990027/S004. Feb 25, 2003. <http://www.fda.gov/cdrh/pdf/p990027s004.html> (accessed Nov 11, 2005).

- 47 US FDA. VISX STAR S2 and S3 Excimer Laser Systems. P930016/S012. April 27, 2001. <http://www.fda.gov/cdrh/pdf/p930016s012.html> (accessed Nov 11, 2005).
- 48 US FDA. WaveLight ALLEGRETTO WAVE™ Excimer Laser System. P030008. Oct 10, 2003. <http://www.fda.gov/cdrh/PDF3/p030008.html> (accessed Nov 11, 2005).
- 49 US FDA. STAR S4™ Excimer Laser System with Variable Spot Scanning (VSS™) and WaveScan WaveFront® System. P930016/S017. Dec 14, 2004. <http://www.fda.gov/cdrh/pdf/p930016s017.html> (accessed Nov 11, 2005).
- 50 Lee JB, Kim JS, Choe C, Seong GJ, Kim EK. Comparison of two procedures: photorefractive keratectomy versus laser in situ keratomileusis for low to moderate myopia. *Jpn J Ophthalmol* 2001; 45: 487–91.
- 51 el Danasoury MA, el Maghraby A, Klyce SD, Mehrez K. Comparison of photorefractive keratectomy with excimer laser in situ keratomileusis in correcting low myopia (from -2.00 to -5.50 diopters): a randomized study. *Ophthalmology* 1999; 106: 411–21.
- 52 El-Maghraby A, Salah T, Waring GO 3rd, Klyce S, Ibrahim O. Randomized bilateral comparison of excimer laser in situ keratomileusis and photorefractive keratectomy for 2.50 to 8.00 diopters of myopia. *Ophthalmology* 1999; 106: 447–57.
- 53 Kaya V, Oncel B, Sivrikaya H, Yilmaz OF. Prospective, paired comparison of laser in situ keratomileusis and laser epithelial keratomileusis for myopia less than -6.00 diopters. *J Refract Surg* 2004; 20: 223–28.
- 54 Lin JM, Tsai YY. Laser in situ keratomileusis for different degrees of myopia. *Acta Ophthalmol Scand* 2005; 83: 40–45.
- 55 Knorz MC, Neuhann T. Treatment of myopia and myopic astigmatism by customized laser in situ keratomileusis based on corneal topography. *Ophthalmology* 2000; 107: 2072–76.
- 56 Hersh PS, Brint SF, Maloney RK, et al. Photorefractive keratectomy versus laser in situ keratomileusis for moderate to high myopia: a randomized prospective study. *Ophthalmology* 1998; 105: 1512–23.
- 57 Steinert RF, Hersh PS, Summit technology PRK-LASIK study group. Spherical and aspherical photorefractive keratectomy and laser in-situ keratomileusis for moderate to high myopia: two prospective, randomized clinical trials.. *Trans Am Ophthalmol Soc* 1998; 96: 197–227.
- 58 Malecaze FJ, Hulin H, Bierer P, et al. A randomized paired eye comparison of two techniques for treating moderately high myopia: LASIK and Artisan phakic lens. *Ophthalmology* 2002; 109: 1622–30.
- 59 El Danasoury MA, El Maghraby A, Gamali TO. Comparison of iris-fixed Artisan lens implantation with excimer laser in situ keratomileusis in correcting myopia between -9.00 and -19.50 diopters: a randomized study. *Ophthalmology* 2002; 109: 955–64.
- 60 Kim TI, Yang SJ, Tchah H. Bilateral comparison of wavefront-guided versus conventional laser in situ keratomileusis with Bausch and Lomb Zyoptix. *J Refract Surg* 2004; 20: 432–38.
- 61 Sekundo W, Bonicke K, Mattausch P, Wiegand W. Six-year follow-up of laser in situ keratomileusis for moderate and extreme myopia using a first-generation excimer laser and microkeratome. *J Cataract Refract Surg* 2003; 29: 1152–58.
- 62 Esquenazi S. Five-year follow-up of laser in situ keratomileusis for hyperopia using the Technolas Keracor 117C excimer laser. *J Refract Surg* 2004; 20: 356–63.
- 63 Varley GA, Huang D, Rapuano CJ, et al. LASIK for hyperopia, hyperopic astigmatism, and mixed astigmatism: a report by the American Academy of Ophthalmology. *Ophthalmology* 2004; 111: 1604–17.
- 64 Salz JJ, Stevens CA. LASIK correction of spherical hyperopia, hyperopic astigmatism, and mixed astigmatism with the LADARVision excimer laser system. *Ophthalmology* 2002; 109: 1647–58.
- 65 Rashad KM. Laser in situ keratomileusis for the correction of hyperopia from +1.25 to +5.00 diopters with the Technolas Keracor 117C laser. *J Refract Surg* 2001; 17: 113–22.
- 66 Cobo-Soriano R, Llovet F, Gonzalez-Lopez F, Domingo B, Gomez-Sanz F, Baviera J. Factors that influence outcomes of hyperopic laser in situ keratomileusis. *J Cataract Refract Surg* 2002; 28: 1530–38.
- 67 Albarrán-Diego C, Muñoz G, Montés-Micó R, Alió JL. Bitoric laser in situ keratomileusis for astigmatism. *J Cataract Refract Surg* 2004; 30: 1471–78.
- 68 Handzel A, Kenikstul N, Handzel T. Laser in situ keratomileusis for astigmatism greater than -3.50 D with the Nidek EC-5000 excimer laser. *J Refract Surg* 2003; 19 (2 suppl): S241–42.
- 69 Alio JL, Javaloy J, Osman AA, Galvis V, Tello A, Haroun HE. Laser in situ keratomileusis to correct post-keratoplasty astigmatism; 1-step versus 2-step procedure. *J Cataract Refract Surg* 2004; 30: 2303–10.
- 70 Norouzi H, Rahmati-Kamel M. Laser in situ keratomileusis for correction of induced astigmatism from cataract surgery. *J Refract Surg* 2003; 19: 416–24.
- 71 Visx Technology. News and events. May 31, 2005. http://www.visx.com/professionals/news_events/ (accessed Nov 11, 2005).
- 72 Telandro A. Pseudo-accommodative cornea: a new concept for correction of presbyopia. *J Refract Surg* 2004; 20 (suppl 5): S714–17.
- 73 Bauerberg JM. Centered vs. inferior off-center ablation to correct hyperopia and presbyopia. *J Refract Surg* 1999; 15: 66–69.
- 74 Cantu R, Rosales MA, Tepichin E, Curioa A, Montes V, Bonilla J. Advanced surface ablation for presbyopia using the Nidek EC-5000 laser. *J Refract Surg* 2004; 20 (5 suppl): S711–13.
- 75 Miranda D, Krueger RR. Monovision laser in situ keratomileusis for pre-presbyopic and presbyopic patients. *J Refract Surg* 2004; 20: 325–28.
- 76 Jain S, Ou R, Azar DT. Monovision outcomes in presbyopic individuals after refractive surgery. *Ophthalmology* 2001; 108: 1430–33.
- 77 US FDA. ALCON Apex & Apex Plus. P930034. <http://www.fda.gov/cdrh/pdf/p930034.pdf> (accessed Oct 25, 1995).
- 78 Hashemi H, Fotouhi A, Foudazi H, Sadeghi N, Payvar S. Prospective, randomized, paired comparison of laser epithelial keratomileusis and photorefractive keratectomy for myopia less than -6.50 diopters. *J Refract Surg* 2004; 20: 217–22.
- 79 Lee JB, Seong GJ, Lee JH, Seo KY, Lee YG, Kim EK. Comparison of laser epithelial keratomileusis and photorefractive keratectomy for low to moderate myopia. *J Cataract Refract Surg* 2001; 27: 565–70.
- 80 Pop M, Payette Y. Photorefractive keratectomy versus laser in situ keratomileusis: a control-matched study. *Ophthalmology* 2000; 107: 251–57.
- 81 Shah S, Chatterjee A, Smith RJ. Predictability and outcomes of photoastigmatic keratectomy using the Nidek EC-5000 excimer laser. *J Cataract Refract Surg* 2002; 28: 682–88.
- 82 MacRae SM, Peterson JS, Koch DD, Rich LF, Durrie DS. Photoastigmatic refractive keratectomy in myopes. Nidek US Investigators Group. *J Refract Surg* 2000; 16: 122–32.
- 83 Kapadia MS, Wilson SE. One-year results of PRK in low and moderate myopia: fewer than 0.5% of eyes lose two or more lines of vision. *Cornea* 2000; 19: 180–84.
- 84 Tole DM, McCarty DJ, Couper T, Taylor HR. Comparison of laser in situ keratomileusis and photorefractive keratectomy for the correction of myopia of -6.00 diopters or less. Melbourne Excimer Laser Group. *J Refract Surg* 2001; 17: 46–54.
- 85 Kim JK, Kim SS, Lee HK, et al. Laser in situ keratomileusis versus laser-assisted subepithelial keratectomy for the correction of high myopia. *J Cataract Refract Surg* 2004; 30: 1405–11.
- 86 Partial AE, Rojas MC, Manche EE. Analysis of the efficacy, predictability, and safety of LASEK for myopia and myopic astigmatism using the Technolas 217 excimer laser. *J Cataract Refract Surg* 2004; 30: 2138–44.
- 87 Lee HK, Lee KS, Kim JK, Kim HC, Seo KR, Kim EK. Epithelial healing and clinical outcomes in excimer laser photorefractive surgery following three epithelial removal techniques: mechanical, alcohol, and excimer laser. *Am J Ophthalmol* 2005; 139: 56–63.
- 88 Claringbold TV, 2nd. Laser-assisted subepithelial keratectomy for the correction of myopia. *J Cataract Refract Surg* 2002; 28: 18–22.
- 89 Autrata R, Rehurek J. Laser-assisted subepithelial keratectomy and photorefractive keratectomy for the correction of hyperopia: results of a 2-year follow-up. *J Cataract Refract Surg* 2003; 29: 2105–14.
- 90 Nagy ZZ, Krueger RR, Suveges I. Photorefractive keratectomy for astigmatism with the Meditec MEL 60 laser. *J Refract Surg* 2001; 17: 441–53.

- 91 Nagy ZZ, Palagyi-Deak I, Kovacs A, Kelemen E, Forster W. First results with wavefront-guided photorefractive keratectomy for hyperopia. *J Refract Surg* 2002; **18**: S620–23.
- 92 Netto MV, Mohan RR, Ambrosio R Jr, Hutcheon AE, Zieske JD, Wilson SE. Wound healing in the cornea: a review of refractive surgery complications and new prospects for therapy. *Cornea* 2005; **24**: 509–22.
- 93 Melki SA, Azar DT. LASIK complications: etiology, management, and prevention. *Surv Ophthalmol* 2001; **46**: 95–116.
- 94 Davidorf JM, Zaldivar R, Oscherow S. Results and complications of laser in situ keratomileusis by experienced surgeons. *J Refract Surg* 1998; **14**: 114–22.
- 95 Shah MN, Misra M, Wilhelmus KR, Koch DD. Diffuse lamellar keratitis associated with epithelial defects after laser in situ keratomileusis. *J Cataract Refract Surg* 2000; **26**: 1312–18.
- 96 Kohnen T, Terzi E, Mirshahi A, Bühren J. Intraindividual comparison of epithelial defects during laser in situ keratomileusis using standard and zero-compression Hansatome microkeratome heads. *J Cataract Refract Surg* 2004; **30**: 123–26.
- 97 Kenyon KR, Paz H, Greiner JV, Gipson IK. Corneal epithelial adhesion abnormalities associated with LASIK. *Ophthalmology* 2004; **111**: 11–17.
- 98 Tekwani NH, Huang D. Risk factors for intraoperative epithelial defect in laser in-situ keratomileusis. *Am J Ophthalmol* 2002; **134**: 311–16.
- 99 Lin RT, Maloney RK. Flap complications associated with lamellar refractive surgery. *Am J Ophthalmol* 1999; **127**: 129–36.
- 100 Stulting RD, Carr JD, Thompson KP, Waring GO 3rd, Wiley WM, Walker JG. Complications of laser in situ keratomileusis for the correction of myopia. *Ophthalmology* 1999; **106**: 13–20.
- 101 Noda-Tsuruya T, Toda I, Asano-Kato N, Hori-Komai Y, Fukumoto T, Tsubota K. Risk factors for development of diffuse lamellar keratitis after laser in situ keratomileusis. *J Refract Surg* 2004; **20**: 72–75.
- 102 Thammano P, Rana AN, Talamo JH. Diffuse lamellar keratitis after laser in situ keratomileusis with the Moria LSK-One and Carriazo-Barraquer microkeratomes. *J Cataract Refract Surg* 2003; **29**: 1962–68.
- 103 Hoffman RS, Fine IH, Packer M. Incidence and outcomes of LASIK with diffuse lamellar keratitis treated with topical and oral corticosteroids. *J Cataract Refract Surg* 2003; **29**: 451–56.
- 104 Johnson JD, Harissi-Dagher M, Pineda R, Yoo S, Azar DT. Diffuse lamellar keratitis: incidence, associations, outcomes, and a new classification system. *J Cataract Refract Surg* 2001; **27**: 1560–66.
- 105 Stulting RD, Randleman JB, Couser JM, Thompson KP. The epidemiology of diffuse lamellar keratitis. *Cornea* 2004; **23**: 680–88.
- 106 Lindstrom RL, Hardten DR, Houtman DM, et al. Six-month results of hyperopic and astigmatic LASIK in eyes with primary and secondary hyperopia. *Trans Am Ophthalmol Soc* 1999; **97**: 241–60.
- 107 Price FW Jr, Willes L, Price M, Lyng A, Ries J. A prospective, randomized comparison of the use versus non-use of topical corticosteroids after laser in situ keratomileusis. *Ophthalmology* 2001; **108**: 1236–45.
- 108 Nakano K, Nakano E, Oliveira M, Portellinha W, Alvarenga L. Intraoperative microkeratome complications in 47,094 laser in situ keratomileusis surgeries. *J Refract Surg* 2004; **20** (5 suppl): S723–26.
- 109 Asano-Kato N, Toda I, Hori-Komai Y, Takano Y, Tsubota K. Epithelial ingrowth after laser in situ keratomileusis: clinical features and possible mechanisms. *Am J Ophthalmol* 2002; **134**: 801–07.
- 110 Wang MY, Maloney RK. Epithelial ingrowth after laser in situ keratomileusis. *Am J Ophthalmol* 2000; **129**: 746–51.
- 111 Walker MB, Wilson SE. Incidence and prevention of epithelial growth within the interface after laser in situ keratomileusis. *Cornea* 2000; **19**: 170–73.
- 112 Yildirim R, Devranoglu K, Ozdamar A, Aras C, Ozkiris A, Ozkan S. Flap complications in our learning curve of laser in situ keratomileusis using the Hansatome microkeratome. *Eur J Ophthalmol* 2001; **11**: 328–32.
- 113 Vesaluoma M, Perez-Santonja J, Petroll WM, Linna T, Alio J, Tervo T. Corneal stromal changes induced by myopic LASIK. *Invest Ophthalmol Vis Sci* 2000; **41**: 369–76.
- 114 Chang MA, Jain S, Azar DT. Infections following laser in situ keratomileusis: an integration of the published literature. *Surv Ophthalmol* 2004; **49**: 269–80.
- 115 Gimbel HV, van Westenbrugge JA, Penno EE, Ferensowicz M, Feinerman GA, Chen R. Simultaneous bilateral laser in situ keratomileusis: safety and efficacy. *Ophthalmology* 1999; **106**: 1461–68.
- 116 Rad AS, Jabbarvand M, Saifi N. Progressive keratectasia after laser in situ keratomileusis. *J Refract Surg* 2004; **20**(5 Suppl): S718–22.
- 117 Calvillo MP, McLaren JW, Hodge DO, Bourne WM. Corneal reinnervation after LASIK: prospective 3-year longitudinal study. *Invest Ophthalmol Vis Sci* 2004; **45**: 3991–96.
- 118 Azar DT, Jain S. Topical MMC for subepithelial fibrosis after refractive corneal surgery. *Ophthalmology* 2001; **108**: 239–40.
- 119 Thom SB, Myers JS, Rapuano CJ, Eagle RC Jr, Siepser SB, Gomes JA. Effect of topical anti-transforming growth factor- β on corneal stromal haze after photorefractive keratectomy in rabbits. *J Cataract Refract Surg* 1997; **23**: 1324–30.
- 120 Zaldivar R, Davidorf JM, Oscherow S, Ricur G, Piezzi V. Combined posterior chamber phakic intraocular lens and laser in situ keratomileusis: bioptics for extreme myopia. *J Refract Surg* 1999; **15**: 299–308.